



## ORIGINAL ARTICLE

# Comparison of laminoplasty and posterior segment fusion with laminoplasty and anterior segment fusion for treating acute extensional cervical spinal cord injury in pre-existing canal stenosis: a multicenter retrospective study

Hao Lv<sup>1†</sup>, Xuan Zou<sup>2†</sup>, Jiachao Xiong<sup>1†</sup>, Zhenhai Zhou<sup>1</sup>, Junlong Zhong<sup>1</sup>, Shengbiao Ma<sup>1</sup>, Wenbing Wan<sup>3</sup>, Bi Zhang<sup>4</sup>, Jiaquan Luo<sup>5</sup>, Qiang Xiao<sup>6</sup>, Kai Cao<sup>1</sup>

<sup>1</sup>Orthopedic Hospital, The First Affiliated Hospital, Jiangxi Medical College, Nanchang University, Nanchang, Jiangxi Province, China, <sup>2</sup>Department of Orthopedic Surgery, The Second Hospital of Jingdezhen City, Jingdezhen City, Jiangxi Province, China, <sup>3</sup>Department of Orthopedic Surgery, The Second Affiliated Hospital of Nanchang University, Nanchang, Jiangxi Province, China, <sup>4</sup>Department of Orthopedic Surgery, The Affiliated Ganzhou Hospital of Nanchang University, Ganzhou, Jiangxi Province, China, <sup>5</sup>Department of Orthopedic Surgery, The First Affiliated Hospital of Gannan Medical College, Ganzhou, Jiangxi Province, China, <sup>6</sup>Department of Orthopedic Surgery, The People's Hospital of Jiangxi Province, Nanchang, Jiangxi Province, China

## ARTICLE INFO

*Article history:*

Received: February 19, 2023

Accepted: December 19, 2023

Published online: February 1, 2024

*Keywords:*

Extensional cervical spinal cord injury

Cervical spinal canal stenosis

Laminoplasty

Posterior short-segment fusion

Anterior cervical discectomy and fusion

Clinical efficacy

*\*Corresponding author:*

Kai Cao

Orthopedic Hospital, The First Affiliated Hospital of Nanchang University, Nanchang (330209), Jiangxi Province, China.

Email: kaichaw@126.com

© 2024 Author(s). This is an Open-Access article distributed under the terms of the Creative Commons Attribution-Noncommercial License, permitting all non-commercial use, distribution, and reproduction in any medium, provided the original work is properly cited.

## ABSTRACT

**Background:** Patients with pre-existing cervical spinal canal stenosis (CSCS) are more likely to suffer from an extensional spinal cord injury (SCI). However, the appropriate surgical alternatives for extended cervical SCIs in individuals with pre-existing CSCS remain unknown. The purpose of this study was to evaluate the clinical efficacies of laminoplasty and posterior short-segment fusion (PSF) with laminoplasty and anterior short-segment fusion (ASF) in the treatment of these patients.

**Methods:** The clinical data of 258 patients from six spine centers were included in this retrospective study. Patients were divided into two different groups based on the surgical approach: laminoplasty and PSF (PSF group) and laminoplasty and ASF (ASF group). ASIA grades and JOA scores were obtained before and after surgery to assess neurological function.

**Results:** There were 116 patients in the PSF group and 142 patients in the ASF group. The average operation time, intraoperative blood loss, and hospital stay were 188 min, 298 ml, and 7.6 days, respectively, in PSF group, compared to 245 min, 366 ml, and 10.4 days in PSF group, respectively. Complete decompression was achieved in all patients, and fusion was achieved 6 months after surgery. A post-operative computed tomography scan revealed that 39/464 (8.4%) screws had perforated, but no neurovascular complications occurred. Both surgical strategies improved the ASIA grade and there was no significant difference between the two groups ( $P = 0.926$ ). The JOA score improved from  $6.21 \pm 1.85$  to  $10.90 \pm 3.56$  in the PSF group and from  $6.45 \pm 2.17$  to  $11.48 \pm 3.62$  in the ASF group, but at the final follow-up, there was no significant difference between the two groups ( $P = 0.134$ ). The incidence of post-operative complications in the ASF group (24/142, 16.9%) ( $P = 0.043$ ) was higher than that in the PSF group (6/116, 5.17%).

**Conclusions:** Cervical laminoplasty combined with short-segment transpedicular screw fixation is a reliable option to treat extensional cervical SCIs in patients with CSCS. This surgical strategy is beneficial for achieving sufficient cervical spinal cord decompression, preserving cervical spine stability, and avoiding extra anterior cervical decompression and fusion, thereby reducing surgery time, intraoperative blood loss volume, post-operative complication rate, and length of hospital stay.

**Relevance for Patients:** Cervical laminoplasty combined with posterior segmental fusion (PSF) reduces operative time, bleeding, and complications and achieves adequate spinal cord decompression in the treatment of extension cervical SCI in patients with CSCS.

## 1. Introduction

Cervical spinal canal stenosis (CSCS) is a disorder in which the spinal cord or nerve roots are compressed, resulting in symptoms such as pain, paraesthesia, and dyskinesia. Pre-existing cervical spondylotic changes, cervical ossification of the posterior longitudinal ligament, or developmental cervical stenosis are the most common pathologic mechanisms leading to CSCS [1,2]. A hyperextension injury, which is accompanied by anterior longitudinal ligament rupture, intervertebral disc destruction, or cervical fracture-dislocation, induces cervical instability and raises the risk of cervical spinal cord injury (SCI) due to pre-existing CSCS [3]. Anterior longitudinal ligament and intervertebral disc rupture are common findings on magnetic resonance imaging (MRI) in patients with a hyperextension cervical injury without fracture or dislocation [1,4,5]. The risk of cervical instability demands surgical stabilization to prevent additional harm.

Cervical laminoplasty is a preferred technique to achieve complete decompression in patients with an extensional cervical spinal injury coupled with multilevel cervical stenosis. Moreover, an extra-anterior approach fusion at the disruption level is required to stabilize the cervical spine after laminoplasty. Despite the ability to achieve both complete decompression and satisfactory reconstruction, the posterior-anterior combined approach is criticized for necessitating a longer surgery time and triggering complications. Therefore, we advocate only the posterior approach, including laminoplasty and segment transpedicular screw fixation, to achieve both decompression and stabilization. In this study, we compared the clinical outcomes of different surgery regimens, such as laminoplasty combined with anterior fusion and laminoplasty associated with transpedicular screw instrumentation, to treat extensional cervical spinal injury in patients with CSCS.

## 2. Materials and Methods

### 2.1. Study participants

The clinical data of 258 patients with acute extensional cervical spinal injuries and pre-existing CSCS who were admitted to six spine centers between April 2010 and January 2022 were recruited for this retrospective study. Patients with the following characteristics were enrolled: aged 18 – 70 years, sustained an extensional cervical spinal injury within 24 h, suffered from pre-existing degenerative cervical stenosis, and developed cervical stenosis or stenosis involving ossification of the cervical posterior longitudinal ligament (OPLL). Patients with cervical dislocation, cervical infection, tumor, tuberculous disease, and brain injury were excluded from this study. The disrupted anterior longitudinal ligament or intervertebral disc was confirmed by gradient-echo T2 (T2-weighted GRE) and STIR-weighted MRI pulse sequences. The present study was approved by the institutional review board of each participating hospital.

### 2.2. Surgical procedures

In the laminoplasty and posterior short-segment fusion group, each patient was positioned in a Concorde position after being

administered general anesthesia. Using the posterior middle approach, the extensional muscles were detached from the spinous process and lamina to expose the mass from C3 to C6. If C7 was involved, the C7 articular mass also needed to be exposed. The lateral margin of the articular masses of the injured level needs to be extra-exposed. The notch-referred technique was used to place cervical pedicle screws (CPS) [6]. Being virtually unaffected by bony encumbrances or erosive articular surface variants, the lateral vertebral notch is a reliable and consistent anatomical landmark for lower-axis CPS placement, providing an accurate and safe reference point for subaxial CPS placement. When short-segmental transpedicular screw instrumentation was completed in the involved cervical spine, laminoplasty was conducted from C3 to C6 (C7 may be necessary if involved). By sparing the nerve roots and spinal cord and enlarging the spinal canal, surgery reduces the pressure on the spinal cord and nerve roots. At the end of the procedure, the surgeon closed the incision layer by layer to promote healing [7]. In the treatment of a cervical SCI without fracture or dislocation, single-opening laminoplasty has satisfactory efficacy in the recovery of post-operative neurological function, reduction of pain, and improvement of daily life behaviors compared to total laminectomy with lateral mass screw fixation. Moreover, single-opening laminoplasty achieves lesser trauma and is associated with a lower complication rate. Therefore, given its advantages, posterior single-opening laminoplasty coupled with pedicle screw fixation was our preferred choice of surgical plan. The facets and masses were decorticated and bone grafted for fusion (Figure 1). In the laminoplasty and anterior short segment fusion group, the patient was initially placed in a prone position to receive laminoplasty and then placed in a supine position to be treated with anterior discectomy and fusion at the involved intervertebral disc.

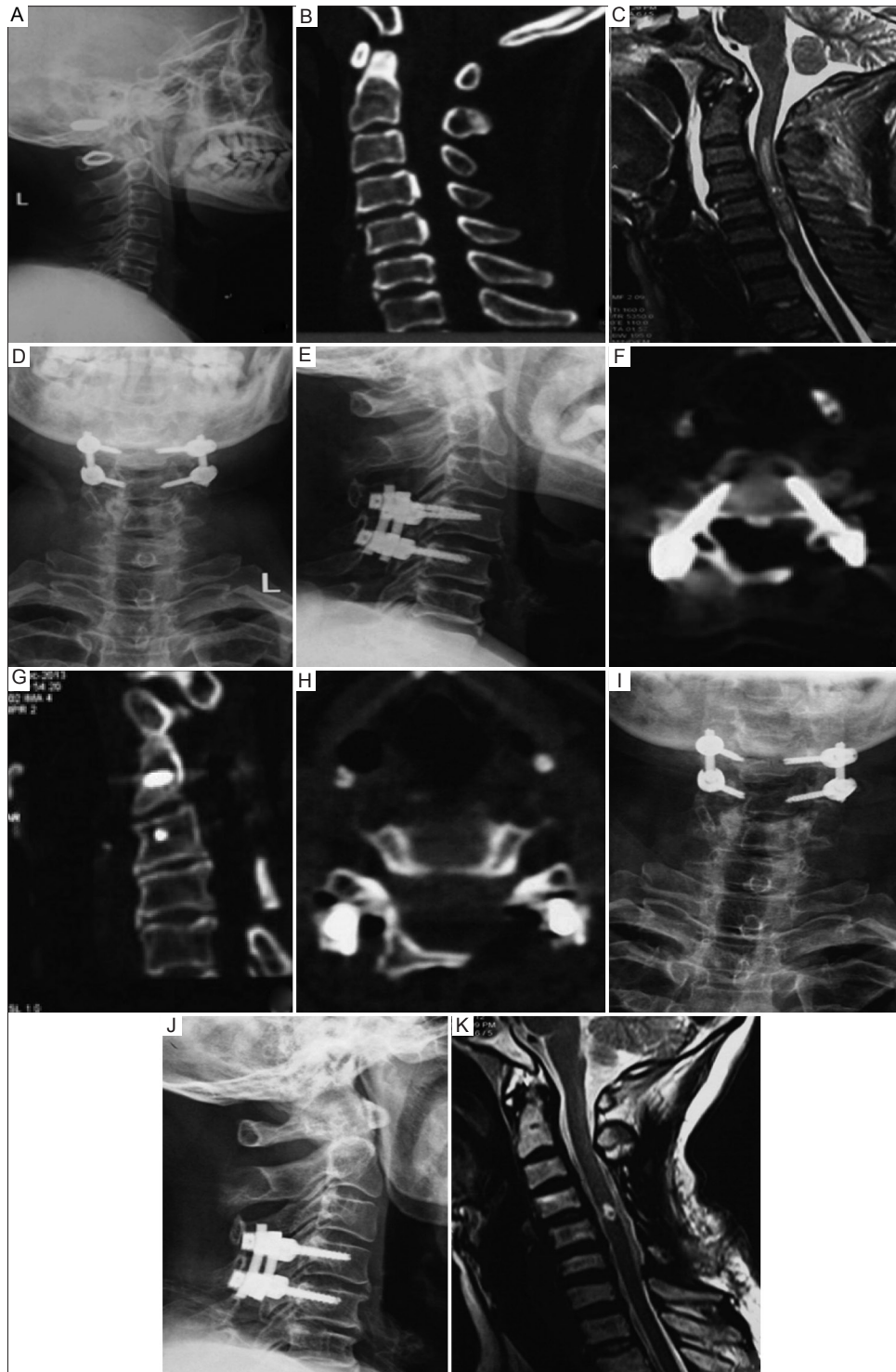
### 2.3. Clinical assessment

Routine post-operative X-ray, computed tomography (CT), and MRI examinations were performed to confirm the instrument's position and the adequacy of decompression (Figure 1). In addition, all patients performed neurofunctional rehabilitation exercises in the rehabilitation department soon after surgery. Post-operative and follow-up assessments were performed to assess and determine the neurological function (ASIA scale and JOA score), bone-graft fusion, instrument's location, surgery time, intraoperative blood loss volume, and length of hospital stay of the patients in the two groups. The improvement rate of neurological function was calculated using the following formula:

$$\text{Improvement rate of neurological function(\%)} = \frac{\text{Postoperative JOA score} - \text{Preoperative JOA score}}{17 - \text{preoperative JOA score}} \times 100$$

### 2.4. Statistical analyses

Continuous variables between the two groups were compared using *t*-test. Chi-squared tests were used to compare categorical variables between the two groups. The software package IBM SPSS Statistics version 22 (IBM, USA) was used to perform



**Figure 1.** Laminoplasty with short-segmental transpedicular screw fixation in treating extensional cervical injuries in patients with cervical spinal canal stenosis (CSCS). Pre-operative lateral X-ray and sagittal computed tomography (CT) scans showed CSCS and segmental ossification of the posterior longitudinal ligament at C4-C5 (A and B). Pre-operative sagittal T2-weighted images showed an inhomogeneous high signal intensity of the cervical cord extending from C3 to C6. A swollen cervical cord, discontinuity of the anterior longitudinal ligament, and disc rupture at C4/5 were observed (C). X-ray immediately after the surgery showed that the screws were inserted in the appropriate position and that the osseous cervical canal was significantly expanded after laminoplasty from C3 to C6 (D and E). Horizontal CT scan showed that the screw trajectories were appropriate (F). A sagittal CT scan further confirmed that the osseous cervical canal was significantly expanded after laminoplasty (G). The horizontal CT scan 6 months after surgery showed that the hinged side of the cervical lamina was fused (H). The X-ray one year after surgery showed a good position of internal fixation. (I-J) Magnetic resonance imaging scan conducted 24 months after the surgery indicated that the cervical canal remained expanded and that post-traumatic syringomyelia had developed (K).

the statistical analyses. Results with a  $P < 0.05$  were considered statistically significant.

### 3. Results

**Figure 1.** Laminoplasty with short-segmental transpedicular screw fixation in treating extensional cervical injuries in patients with cervical spinal canal stenosis (CSCS). Pre-operative lateral X-ray and sagittal computed tomography (CT) scans showed CSCS and segmental ossification of the posterior longitudinal ligament at C4-C5 (A and B). Pre-operative sagittal T2-weighted images showed an inhomogeneous high signal intensity of the cervical cord extending from C3 to C6. A swollen cervical cord, discontinuity of the anterior longitudinal ligament, and disc rupture at C4/5 were observed (C). X-ray immediately after the surgery showed that the screws were inserted in the appropriate position and that the osseous cervical canal was significantly expanded after laminoplasty from C3 to C6 (D and E). Horizontal CT scan showed that the screw trajectories were appropriate (F). A sagittal CT scan further confirmed that the osseous cervical canal was significantly expanded after laminoplasty (G). The horizontal CT scan 6 months after surgery showed that the hinged side of the cervical lamina was fused (H). The X-ray one year after surgery showed a good position of internal fixation. (I-J) Magnetic resonance imaging scan conducted 24 months after the surgery indicated that the cervical canal remained expanded and that post-traumatic syringomyelia had developed (K).

Two hundred and fifty-eight patients grappling with acute extensional cervical spinal injuries, as confirmed by MRI, and pre-existing CSCS were followed up. One hundred and sixteen patients who underwent posterior laminoplasty and received transpedicular screw implantation were included in the PSF group. One hundred forty-two patients who underwent laminoplasty combined with anterior fusion were included in the ASF group. The mean follow-up time was  $23.5 \pm 2.8$  months. The demographic characteristics of the patients are shown in [Table 1](#), which shows that the patient profiles were not significantly different between the two groups.

#### 3.1. Surgery time, blood loss, and length of hospital stay

In the PSF group, the average surgery time was  $188 \pm 23$  minutes, intraoperative blood loss was  $298 \pm 42$  ml, and length of hospital stay was  $7.6 \pm 2.9$  days. However, in the ASF group, the average surgery time was  $245 \pm 25$  min, intraoperative blood loss was  $366 \pm 51$  ml, and length of hospital stay was  $10.4 \pm 3.3$  days, which significantly outstripped those in the PSF group. The results are shown in [Table 2](#).

#### 3.2. Complications

All patients showed complete decompression on radiography, and bone fusion was achieved 6 months postoperatively. A post-operative CT scan revealed that 39 screws (8.4%) of 464 screws perforated the cortex of the pedicles. However, no neurovascular complications were involved. One patient in the ASF group died of respiratory failure. A total of 30 complications occurred, including

lung infection, cranial spinal fluid leakage, surficial wound infection, dysphagia, and instrument failure in both groups, but the occurrence rate significantly differed between the two groups. Four instrument failures occurred in the ASF group, including dislodged plates, although good positioning of anterior fixation was verified intra-operatively. An additional revisional surgery was conducted for instrument failure. The results are shown in [Table 2](#).

#### 3.3. Neurological function improvement and analysis

Preoperatively, 258 patients had neurological deficits with ASIA grades C (50%) and B (31.4%), followed by grades D (11.6%) and A (7.0%). After surgery, the neurological function of patients in both groups improved to ASIA grades D (43.8%) and C (26.0%), followed by grades E (13.5%), B (12.8%), and A (3.9%). The assessments of the ASIA grades are shown in [Table 3](#).

The mean pre-operative JOA score was  $6.21 \pm 1.85$  in the PSF group and  $6.45 \pm 2.17$  in the ASF group. The mean final follow-up JOA score was  $10.90 \pm 3.56$  in the PSF group and  $11.48 \pm 3.62$  in the ASF group, without a significant difference. The recovery rate was 43.5% in the PSF group and 47.7% in the ASF group, and no significant difference was found between the groups ( $P > 0.05$ ). The results are shown in [Table 4](#).

**Table 1.** Demographic data of the patients

General information	PSF group (n=116)	ASF group (n=142)	P-value
Age (years)	47.8±8.7	48.6±8.2	0.446
Sex			
Male	87	101	0.486
Female	29	41	
Injury time (h)	4.9±2.4	5.1±2.9	0.548
Injured level			
C2/3	2 (1.7%)	5 (3.5%)	0.850
C3/4	14 (12.1%)	19 (13.4%)	
C4/5	55 (47.4%)	70 (49.3%)	
C5/6	39 (33.6%)	41 (28.9%)	
C6/7	6 (5.2%)	7 (4.9%)	

Abbreviations: PSF: Posterior short-segment fusion, ASF: Anterior short segment fusion

**Table 2.** Surgery time, blood loss, length of hospital stay, and complications between the two groups

Surgery-related index	PSF group (n=116)	ASF group (n=142)	P-value
Surgery time (min)	188±23	245±25	<0.001
Blood loss (ml)	298±42	366±51	<0.001
Length of hospital stay (days)	7.6±2.9	10.4±3.3	<0.001
Complications	6	24	
CSF leaking	3	1	0.043
Lung infection	1	7	
Wound infection	2	8	
Instrument failure	0	4	
Dysphagia	0	4	

Abbreviations: CSF: Cranial spinal fluid, PSF: Posterior short-segment fusion, ASF: Anterior short segment fusion

**Table 3.** Comparison of pre-operative and final follow-up ASIA grades between the two groups

ASIA grades	PSF group (n=116) (%)	ASF group (n=142) (%)	Total (n=258)	P-value
Pre-operative ASIA grades				
A	7 (6.0)	11 (7.7)	18 (7.0)	0.690
B	39 (33.6)	42 (29.6)	81 (31.4)	
C	59 (50.9)	70 (49.3)	129 (50.0)	
D	11 (9.5)	19 (13.4)	30 (11.6)	
Final follow-up ASIA grades				
A	4 (3.4)	6 (4.2)	10 (3.9)	0.926
B	15 (12.9)	18 (12.7)	33 (12.8)	
C	29 (25.0)	38 (26.8)	67 (26.0)	
D	54 (46.6)	59 (41.5)	113 (43.8)	
E	14 (12.1)	21 (14.8)	35 (13.5)	

Abbreviations: PSF: Posterior short-segment fusion, ASF: Anterior short-segment fusion

**Table 4.** Comparison of pre-operative and final follow-up JOA scores between the two groups

JOA	PSF group (n=116)	ASF group (n=142)	P-value
Pre-operative JOA	6.21±1.85	6.45±2.17	0.345
Final follow-up JOA	10.90±3.56	11.48±3.62	0.134

Abbreviations: PSF: Posterior short-segment fusion, ASF: Anterior short-segment fusion

## 4. Discussion

Owing to the risk for paralysis, sensory impairment, bowel, bladder, and sexual dysfunction, acute cervical SCI is a potentially devastating condition. Individuals with cervical canal stenosis are known to be at high risk for developing cervical SCI when injured. Among cervical SCI patients with cervical stenosis, an extensional injury is the most common injury mechanism and occurs in many patients without any radiological evidence of fracture or dislocation. This injury should be classified as a distractive extension type according to Allen's report or as a B3 type injury according to the AO classification [8], which requires surgical intervention. Extensional injuries are characterized by progressive failure of the motion segment in an anterior-to-posterior direction, which consists of failure of the anterior longitudinal ligament and annulus fibrosus. Widening of the disc space could be seen on the X-ray under extension. There may be a small avulsion fracture at the anterior margin of the disc space in some cases. If extensional force continued, posterior subluxation could occur. It is also common that the magnitude of posterior displacement could often vanish following flexion of the head. Extensional injuries were often the result of a fall on the face. Therefore, for patients with a facial injury who are diagnosed with an SCI even without fracture or dislocation, attention should be given to an extensive cervical spinal injury. In this study, we advocated that cervical laminoplasty combined with transpedicular screw fixation is a preferred approach to treating an extensional cervical spinal injury in patients with stenosis. This study retrospectively analyzed the clinical outcomes of patients who underwent anterior decompression and fusion surgery and those who underwent posterior hybrid surgery [9].

PHT was as effective as ADF in the treatment of cervical SCI, based on the fact that PHT was superior to ADF in improving the patient's health-related quality of life and preserving cervical spine mobility in the long-term follow-up period.

Early decompression surgery for extensional cervical spinal injury had a beneficial outcome [10]. The optimal timing for surgical intervention remains unclear. La Rosa *et al.* [11] reported that early decompression surgery within 24 h of trauma exerted a significantly better effect [12,13] than late surgical management. Guest *et al.* also reported that early surgery (within 24 h of injury) improves overall motor recovery in patients whose traumatic central cord syndrome was related to acute disc herniation or fracture [14]. The patients in this cohort received early decompression, and an obvious improvement in post-surgical neurological scores was observed. In contrast, other studies reported that surgical treatment was not superior to conservative treatment for traumatic CSCI without major fracture or dislocation with spinal cord compression in the acute phase [15-17]. No relationships between pre-existing CSCS and neurological outcomes were evident after traumatic CSCI. These results suggest that decompression surgery might not be recommended for traumatic CSCI without major fracture or dislocation despite pre-existing CSCS. Some results suggest that prophylactic surgical treatment for CSCS may not have a significant impact on the incidence of traumatic CSCI. However, patients with pre-existing CSCS do have an increased incidence of CSCI, which is noteworthy [18]. We considered that the injured cord would be more severely squeezed in patients with a pre-conditioned stenotic canal under the rapid development of edema in the early stage after spinal cord trauma. Therefore, in this scenario, laminoplasty provides a feasible approach for the complete decompression of cervical spinal cord, with multisegmental decompression in particular delivering more effective outcomes. A study has shown that patients with minimal cord changes on MRI have the best outcome, followed by those with cord edema, and patients with parenchymatous hemorrhage and contusion on MRI fare poorly [19]. MRI of the latter cases frequently reveals hematomas and intramedullary edema [20].

According to relevant studies, dynamic changes in the cervical spine and spinal cord in cervical spinal cord injury patients without fractures or dislocations were assessed by kinematic MRI. Kinematic MRI showed dynamic patho-anatomical changes in patients with a cervical SCI, such as spinal stenosis in different locations without fractures or dislocations. The injured segments had small spinal canal diameters, high Muhle grades, little space available for the spinal cord, and a high spinal cord diameter to vertebral canal diameter ratio. MRI techniques can be utilized to examine SCI in patients [21].

Moreover, posterior laminoplasty is a relatively simple procedure that can preserve cervical mobility without engendering substantial post-operative complications. Laminoplasty achieves a decompressive effect for patients with SCI, and the combined anterior spinal fusion in the ASF group as well as the posterior decompression fusion in the PFS group enabled long-term post-operative stabilization, increasing the patient's range of motion and their ability to perform daily activities and ultimately enhancing their post-operative quality of life, which is

not dissimilar to the idea of a study investigating the impact of spinal fusion on quality of life score improvement during the post-operative period [22]. This line of evidence proves that laminoplasty not only can lead to complete decompression but also hinder the development of anterior approach-associated complications in this cohort. Extra anterior approach-related complications, such as dysphagia, were observed in the ASF group, but no analogical complications were observed in the PSF group [23,24].

For patients with OPLL, we also compared the post-operative neurological recovery rates, which were similar in the ASF and PSF groups, as seen in related studies. In patients with giant OPLL with posterior convex malalignment, the neurological recovery rate was better after laminoplasty and ASF than after laminoplasty and PSF. In addition, post-operative neck pain was less severe in the ASF group. However, perioperative complications were more common in the ASF group. Although there was no statistically significant difference in the post-operative nerve recovery rate between the two groups, the recovery rate was higher in the ASF group in patients with kyphosis alignment (C2-C7 angle  $<0^\circ$ ). Post-operative cervical pain was greater and intraoperative blood loss was much more in the PSF group. The improvement in C2-C7 alignment was greater and the operative time was longer in the ASF group. Approach-related complications were more frequently observed in the ASF group than in the PSF group. Drawing upon the comparison between ASF group and PSF group, we concluded that the PSF group benefited substantially from the treatment, the patients in this group were assigned in terms of surgery time, length of hospital stay, blood loss, and complications compared to the ASF group. In the treatment of spinal cervical spondylosis due to OPLL, overall post-operative neurologic function (irrespective of the canal-occupying ratio) was better with the anterior approach than with the posterior approach. We believe that the anterior approach is particularly desirable for patients with a canal-occupancy ratio of  $>50\%$ , although it leads to higher incidences of surgical trauma and surgery-related complications. The posterior approach is relatively safe, with lower rates of surgical trauma and complications. For patients with a canal-occupancy ratio of  $<50\%$ , a posterior approach was recommended, bringing the post-operative neurologic function recovery to a level similar to patients treated with an anterior approach. Therefore, in patients with less severe OPLL, we also recommend the posterior approach for safety reasons and to minimize the chances of developing post-operative complications and patient discomfort. When it comes to treating patients with OPLL, there is no fixed set of criteria to determine the type of treatment because the optimal surgical plan should be decided by the attending surgeon after performing a comprehensive evaluation. Patients in both groups had sufficient decompression verified by post-operative MRI. Laminoplasty decompression conducted in all patients may explain why neurological function recovery was not significantly different between the two groups, as reflected in the post-operative ASIA grades and JOA scores.

Performing immediate post-operative cervical stabilization is another key factor for forestalling secondary injury in patients with an extensional cervical spinal injury. Laminoplasty can sufficiently decompress the stenotic canal, but it could aggravate the stability

of the cervical spine with a pre-existing anterior longitudinal ligament and intervertebral disc disruption. Masaki *et al.* [25] reported that hypermobility of vertebrae at the cord compression level is a risk factor for poor surgical outcomes after laminoplasty. Therefore, stabilization intervention is needed for this cohort with options of extra anterior fusion or posterior instrumentation. Studies have indicated that posterior transpedicular screw fixation is biomechanically stronger than anterior fixation in the cervical spine [26,27]. The strategy of short-segmental fixation was to better preserve the mobility of cervical segments, thereby decreasing the stiffness of the cervical spine, retarding cervical degeneration, and maintaining post-operative range of motion. We found that there were no instrument failures in the PSF group, whereas four instruments became dislodged in the ASF group. Two post-operative fixation displacements occurred due to the excessive intervertebral cage height, which resulted in focal hyperlordosis of the involved segment. Two other instruments became dislodged postoperatively in a patient with hyperextension of the cervical spine.

In this study, compared to laminoplasty combined with anterior fusion procedure, laminoplasty associated with transpedicular screw instrumentation decreased intraoperative blood loss, surgery time, and length hospital stay. This was not difficult to understand because there was only one surgery approach conducted in PSF group associated with less surgical trauma, and patients in this group benefitted more and recovered much faster. Xu and Lun [28] reported that laminoplasty in combination with posterior fixation contributed to several clinical advantages, including less surgical trauma, less intraoperative blood loss, and satisfactory stability in treating multilevel CSCS and SCI in the trauma population. Our results from this comparative study supported Xu and Lun's findings to some extent.

There are some limitations in the study. First, in this retrospective multicenter study, the surgical proficiency for decompression and fixation was not controlled in different institutions. Different expertise in surgery would result in technical bias in the treatment. However, the number of surgeries performed in this study was not small, potentially reducing the risk of bias in the results. Second, although all cases were labeled acute cervical spine injuries within 24 h, it should be noted that controlling the time from injury to surgery in different institutions was a challenging endeavor, which might influence the treatment results in some aspects.

## 5. Conclusion

Cervical laminoplasty combined with short-segment transpedicular screw instrumentation is a reliable and preferred option to treat extensional cervical injuries in patients with pre-existing CSCS. This treatment regimen holds the promise of achieving sufficient cervical spinal cord decompression, instant three-column fixation, and immediate cervical spine restabilization, as well as preventing extra anterior cervical fusion, and reducing post-operative complications.

## Acknowledgments

We thank the staff members from all six spine centers who contributed to this study.

## Funding

This work was supported by Double-Thousand Plan Program of Jiangxi Province, China (No.JXSQ2023201023), Clinical Cultivation Project of the First Affiliated Hospital of Nanchang University, China (No.YFYLCYJPY202202), Key Project of Natural Science Foundation of Jiangxi Province (20202ACB206004).

## Conflict of Interest

The authors declare they have no competing interests.

## Ethics Approval and Consent to Participate

As ours was a retrospective study, no ethical application was required according to the hospital's rules. Written consent was obtained from the patients included in the study.

## Consent for Publication

Written consent was obtained from all patients enrolled in this study.

## Availability of Data

Data are available from the corresponding author upon reasonable request.

## References

- [1] Szwedowski D, Walecki J. Spinal Cord Injury without Radiographic Abnormality (SCIWORA) - Clinical and Radiological Aspects. *Pol J Radiol* 2014;79:461-4. doi: 10.12659/PJR.890944
- [2] Aebli N, Wicki AG, Rüegg TB, Petrou N, Eisenlohr H, Krebs J. The Torg-pavlov Ratio for the Prediction of Acute Spinal Cord Injury After a Minor Trauma to the Cervical Spine. *Spine J* 2013;13:605-12. doi: 10.1016/j.spinee.2012.10.039
- [3] Stemper BD, Yoganandan N, Pintar FA, Rao RD. Anterior Longitudinal Ligament Injuries in Whiplash may Lead to Cervical Instability. *Med Eng Phys* 2006;28:515-24. doi: 10.1016/j.medengphy.2005.09.011
- [4] Zhang JD, Xia Q. Role of Intraoperative Disc Contrast Injection in Determining the Segment Responsible for Cervical Spinal Cord Injury without Radiographic Abnormalities. *Orthop Surg* 2015;7:239-43. doi: 10.1111/os.12197
- [5] Awad BI, Lubelski D, Steinmetz MP. In Reply to the Letter to the Editor Regarding Adjacent Level Ligamentous Injury Associated with Traumatic Cervical Spine Fractures: Indications for Imaging and Implications for Treatment. *World Neurosurg* 2016;86:7. doi: 10.1016/j.wneu.2015.10.017
- [6] Pan Z, Zhong J, Xie S, Yu L, Wu C, Ha Y, *et al.* Accuracy and Safety of Lateral Vertebral Notch-referred Technique used in Subaxial Cervical Pedicle Screw Placement. *Oper Neurosurg (Hagerstown)* 2019;17:52-60. doi: 10.1093/ons/opy233
- [7] Li QW, Wang L, Wang H. A Case-control Study: The Clinical Efficacy of Total Laminectomy with Lateral Mass Screw Fixation and Single Open-door Laminoplasty for Cervical Spinal Cord Injury without Fracture and Dislocation. *Zhongguo Gu Shang* 2022;35:136-41. doi: 10.12200/j.issn.1003-0034.2022.02.009
- [8] Allen BL Jr., Ferguson RL, Lehmann TR, O'Brien RP. A Mechanistic Classification of Closed, Indirect Fractures and Dislocations of the Lower Cervical Spine. *Spine (Phila Pa 1976)* 1982;7:1-27. doi: 10.1097/00007632-198200710-00001
- [9] Wu J, Tao Z, Tang Y, Wang C, Ma J, Lin T, *et al.* Posterior Hybrid Technique for the Treatment of Traumatic Cervical Spinal Cord Injury with High Signal Intensity on T2WI. *Indian J Orthop* 2023;57:768-775. doi: 10.1007/s43465-023-00854-1
- [10] Lee S, Kim C, Ha JK, Jung SK, Park JH. Comparison of Early Surgical Treatment with Conservative Treatment of Incomplete Cervical Spinal Cord Injury without Major Fracture or Dislocation in Patients with Pre-existing Cervical Spinal Stenosis. *Clin Spine Surg* 2021;34:E141-6. doi: 10.1097/BSD.0000000000001065
- [11] La Rosa G, Conti A, Cardali S, Cacciola F, Tomasello F. Does Early Decompression Improve Neurological Outcome of Spinal Cord Injured Patients? Appraisal of the Literature using a Meta-Analytical Approach. *Spinal Cord* 2004;42:503-12. doi: 10.1038/sj.sc.3101627
- [12] Shigematsu H, Cheung JP, Mak KC, Bruzzone M, Luk KD. Cervical Spinal Canal Stenosis First Presenting After Spinal Cord Injury due to Minor Trauma: An Insight into the Value of Preventive Decompression. *J Orthop Sci* 2017;22:22-6. doi: 10.1016/j.jos.2016.09.008
- [13] Wang J, Li J, Cai L. Effects of Treatment of Cervical Spinal Cord Injury without Fracture and Dislocation in a Medium-to long-term Follow-up Study. *World Neurosurg* 2018;113:e515-20. doi: 10.1016/j.wneu.2018.02.071
- [14] Guest J, Eleraky MA, Apostolides PJ, Dickman CA, Sonntag VK. Traumatic Central Cord Syndrome: Results of Surgical Management. *J Neurosurg* 2002;97:25-32. doi: 10.3171/spi.2002.97.1.0025
- [15] Kawano O, Ueta T, Shiba K, Iwamoto Y. Outcome of Decompression Surgery for Cervical Spinal Cord Injury without Bone and Disc Injury in Patients with Spinal Cord Compression: A Multicenter Prospective Study. *Spinal Cord* 2010;48:548-53.

- doi: 10.1038/sc.2009.179
- [16] Takao T, Okada S, Morishita Y, Maeda T, Kubota K, Ideta R, *et al.* Clinical Influence of Cervical Spinal Canal Stenosis on Neurological outcome After Traumatic Cervical Spinal Cord Injury without Major Fracture or Dislocation. *Asian Spine J* 2016;10:536-42.  
doi: 10.4184/asj.2016.10.3.536
- [17] Mazaki T, Ito Y, Sugimoto Y, Koshimune K, Tanaka M, Ozaki T. Does Laminoplasty Really Improve Neurological Status in Patients with Cervical Spinal Cord Injury without Bone and Disc Injury? A Prospective Study about Neurological Recovery and Early Complications. *Arch Orthop Trauma Surg* 2013;133:1401-5.  
doi: 10.1007/s00402-013-1810-x
- [18] Takao T, Morishita Y, Okada S, Maeda T, Katoh F, Ueta T, *et al.* Clinical Relationship between Cervical Spinal Canal Stenosis and Traumatic Cervical Spinal Cord Injury without Major Fracture or Dislocation. *Eur Spine J* 2013;22:2228-31.  
doi: 10.1007/s00586-013-2865-7
- [19] Tewari MK, Gifti DS, Singh P, Khosla VK, Mathuriya SN, Gupta SK, *et al.* Diagnosis and Prognostication of Adult Spinal Cord Injury without Radiographic Abnormality using Magnetic Resonance Imaging: Analysis of 40 Patients. *Surg Neurol* 2005;63:204-9; discussion 209.  
doi: 10.1016/j.surneu.2004.05.042
- [20] Liu A, Qiu NH, Zhong XR, Fang X, Liao JJ, Zhang ZP, *et al.* Dynamic Evaluation of the Cervical Spine by Kinematic MRI in Patients with Cervical Spinal Cord Injury without Fracture and Dislocation. *J Orthop Surg Res* 2023;18:249.  
doi: 10.1186/s13018-023-03745-1
- [21] Li H, Jiang C. Multivariate Analysis of the Operative Effect on Cervical Spinal Cord Injury without Fracture or Dislocation. *Zhongguo Gu Shang* 2020;33:158-65.  
doi: 10.12200/j.issn.1003-0034.2020.02.014
- [22] Cervera Irimia J, Tomé-Bermejo F, Piñera-Parrilla AR, Benito Gallo M, Bisaccia M, Fernández-González M, *et al.* Spinal Fusion Achieves Similar Two-year Improvement in HRqoL as Total Hip and Total Knee Replacement. A Prospective, Multicentric and Observational Study. *SICOT J* 2019;5:26.  
doi: 10.1051/sicotj/2019027
- [23] Feng F, Ruan W, Liu Z, Li Y, Cai L. Anterior Versus Posterior Approach for the Treatment of Cervical Compressive Myelopathy due to Ossification of the Posterior Longitudinal Ligament: A Systematic Review and Meta-analysis. *Int J Surg* 2016;27:26-33.  
doi: 10.1016/j.ijisu.2016.01.038
- [24] Yoshii T, Sakai K, Hirai T, Yamada T, Inose H, Kato T, *et al.* Anterior Decompression with Fusion Versus Posterior Decompression with Fusion for Massive Cervical Ossification of the Posterior Longitudinal Ligament with a  $\geq 50\%$  Canal Occupying Ratio: A Multicenter Retrospective Study. *Spine J* 2016;16:1351-7.  
doi: 10.1016/j.spinee.2016.07.532
- [25] Masaki Y, Yamazaki M, Okawa A, Aramomi M, Hashimoto M, Koda M, *et al.* An Analysis of Factors causing Poor Surgical Outcome in Patients with Cervical Myelopathy Due to Ossification of the Posterior Longitudinal Ligament: Anterior Decompression with Spinal Fusion Versus Laminoplasty. *J Spinal Disord Tech* 2007;20:7-13.  
doi: 10.1097/01.bsd.0000211260.28497.35
- [26] Huang D, Du K, Zeng S, Gao W, Huang L, Su P. The Security Analysis of Transpedicular Screw Fixation in the Lower Cervical Spine and a Case Report. *Spine (Phila Pa 1976)* 2011;36:E1702-8.  
doi: 10.1097/BRS.0b013e31821a5240
- [27] Nakashima H, Yukawa Y, Ito K, Machino M, El Zahlawy H, Kato F. Posterior Approach for Cervical Fracture-dislocations with Traumatic Disc Herniation. *Eur Spine J* 2011;20:387-94.  
doi: 10.1007/s00586-010-1589-1
- [28] Xu ZW, Lun DX. Surgical Management of Multilevel Cervical Spinal Stenosis and Spinal Cord Injury Complicated by Cervical Spine Fracture. *J Orthop Surg Res* 2014;9:77.  
doi: 10.1186/s13018-014-0077-4

#### Publisher's note

AccScience Publishing remains neutral with regard to jurisdictional claims in published maps and institutional affiliations.