



ORIGINAL ARTICLE

Percutaneous pedicle screw fixation combined with percutaneous vertebroplasty for the treatment of thoracic and lumbar metastatic tumors

Xiaowei Ma^{1,2}, Yi Zhao², Jiazheng Zhao², Hongzeng Wu², Helin Feng^{1*}

¹Departments of Orthopedics, National Cancer Center/National Clinical Research Center for Cancer/Cancer Hospital, Chinese Academy of Medical Sciences and Peking Union Medical College, No. 17 Nanli, Panjiayuan, Chaoyang District, Beijing, 100021, China

²Department of Orthopedics, The Fourth Hospital of Hebei Medical University, 12 Health Road, Shijiazhuang 050011, Hebei Province, China

ARTICLE INFO

Article history:

Received: November 8, 2022

Revised: December 6, 2022

Accepted: January 12, 2023

Published online: February 14, 2023

Keywords:

Keywords:

Bone metastases

Percutaneous pedicle screw fixation

Percutaneous vertebroplasty

Thoracic and lumbar disease

Spine

*Corresponding author:

Helin Feng

Departments of Orthopedics, National Cancer Center/National Clinical Research Center for Cancer/Cancer Hospital, Chinese Academy of Medical Sciences and Peking Union Medical College, No. 17 Nanli, Panjiayuan, Chaoyang District, Beijing, 100021, China.
Email: helinfeng0311@163.com

© 2023 Author(s). This is an Open-Access article distributed under the terms of the Creative Commons Attribution-Noncommercial License, permitting all non-commercial use, distribution, and reproduction in any medium, provided the original work is properly cited.

ABSTRACT

Background and Aim: With the greatly prolonged survival of cancer patients, more and more patients develop bone metastasis, especially spinal metastasis. Therefore, it is very important to choose the best surgical plan for patients with spinal metastasis in different conditions. This paper aims to evaluate the clinical efficacy of percutaneous pedicle screw fixation (PPSF) combined with percutaneous vertebroplasty (PVP) for the treatment of thoracic and lumbar metastatic tumors.

Methods: Forty patients with thoracic and lumbar metastatic tumors were treated with PPSF combined with PVP and followed up for 6–33 months. The visual analog scale (VAS) and the Barthel Index of activities of daily living (BIADL) were used to evaluate the pain intensity and quality of life before surgery and at 7 days, 3 months, and 6 months after the treatment.

Results: In this study, a total of 40 patients were followed up for 6–33 months (the mean time was 14.87 months). The VAS scores of all patients were significantly decreased, while the BIADL scores were significantly increased. No patients suffered from complications such as infection, pedicle screw loosening, or polymethylmethacrylate leakage. Spine stability was observed in all surviving patients during the follow-up.

Conclusions: PPSF combined with PVP is a new and viable treatment for thoracolumbar metastases in patients with a poor systemic condition, patients who refuse to undergo a conventional open procedure such as en bloc corpectomy, and in patients with vertebral instability or pathological fracture without significant spinal compression.

Relevance for Patients: Patients with spinal metastases have a great risk of spinal instability and even spinal cord compression while enduring pain. Therefore, timely and appropriate surgical treatment is an effective means to stabilize the spine and avoid spinal cord compression. PPSF combined with PVP is an effective new surgical method for the treatment of multilevel spinal metastases.

1. Introduction

Bone is the third most common metastatic site of malignant tumors after the lung and liver [1]. Unfortunately, once bone metastasis occurs, it is difficult to completely cure it and it is associated with bone-related events such as pain, hypercalcemia, compression of the spinal cord or cauda equina, spinal instability, and pathological fractures, all of which can impair the patient's functional status, cause great pain, and adversely influence the patient's quality of life and survival [2,3].

Many cancer treatments prolong the survival of patients, leading to a significant increase in the incidence of metastatic tumors and spinal metastases, and clinicians should pay more attention to the optimal surgical treatment of spinal metastases. Compared with traditional open spine surgery

techniques, minimally invasive surgery can reduce the surgical risks and post-operative complications [4]. Percutaneous vertebroplasty (PVP) is a minimally invasive technique that has achieved good clinical results in the treatment of spinal metastases [5,6]. PVP is undoubtedly the best treatment for metastatic tumors involving a single segment of the vertebral body or with potential spinal instability. When metastatic tumors involve multiple segments of the vertebral body and the spine is unstable, more reliable methods are needed to stabilize the spine. Percutaneous pedicle screw fixation (PPSF) causes as little damage to the back muscle as possible to avoid ischemic necrosis and denervation, which is conducive to the functional recovery of patients [7]. PPSF combined with PVP is recommended for patients with spinal metastases who have a poor systemic condition or who refuse to undergo a conventional open procedure, such as an anterior approach or total en bloc spondylectomy. It is also suitable for cases where there is vertebral instability or pathological fracture without significant spinal compression. Therefore, this minimally invasive surgical approach is described in this paper, along with an assessment of its feasibility, effectiveness, and safety, which will provide a new idea for clinical treatment.

2. Methods

2.1. Population data

The radiologic and clinical data of patients with multi-segmental thoracolumbar metastases treated with PVP combined with PPSF in our hospital between January 2019 and December 2021 were retrospectively analyzed. This case series included 40 patients with thoracic and lumbar metastatic tumors. The inclusion criteria were as follows: (1) Pathological fractures of the thoracolumbar vertebral body caused by tumor bone metastasis confirmed by post-operative pathology, (2) no spinal cord or nerve injury confirmed by CT and MRI, and no obvious spinal canal occupation, and (3) pre-operative SINS score was 7 – 12, and there was a lesion in the posterior column of the vertebral body, or pre-operative SINS score of 13 – 18. The exclusion criteria were as follows: (1) Absolute contraindication for surgery, for example, severe cardiopulmonary dysfunction, coagulopathy, poor basic condition, or unable to tolerate an operation; (2) pathological fractures due to reasons other than tumor destruction, such as osteoporosis; and (3) neurological symptoms or intraspinal space-occupying, indicating a significant need for decompression. Before the procedure, all participants signed a detailed consent form describing the benefits and risks of the procedure, including but not limited to: PPSF increases the cost of the procedure but may have a modest effect, etc. The review board at our hospital did not require further approval for the use of patient records and images.

2.2. Pre-procedural and post-procedural evaluation

The pain level was evaluated by the visual analog scale (VAS) (0 = No pain, 10 = Intolerable pain). The BIADL was used to evaluate the patients' quality of life (QoL). Before surgical treatment, the patients were examined in detail through X-ray imaging (the patient was in a standing position), computed tomography (CT), magnetic resonance imaging (MRI), and bone

scintigraphy (ECT). These examinations were used to assess the lesions in the affected vertebrae in all patients and the integrity of the bilateral pedicles of the adjacent upper and lower vertebral segments of the affected vertebrae. They were also used to determine the type of lesion (osteogenic, osteolytic, or mixed lesions) and whether epidural spinal cord compression (ESCC) was present (Figure 1A-C). Before surgery, all patients received a lower limb venous ultrasound examination to evaluate the vascular condition of the lower extremity veins. Pathological examination of the vertebral tissue specimens was performed to ascertain the origin of the lesion. After surgical treatment, the patient's surgical site X-ray was obtained to evaluate the position of the pedicle screws and rods, as well as the presence of extravascular polymethylmethacrylate (PMMA) leakage.

2.3. Spinal stability and spinal cord injury assessment

The spinal instability neoplastic score (SINS) system, developed by the Spinal Oncology Study Group, was used to assess spinal stability (Table 1) [8]. Spinal stability was evaluated by six aspects, including spine location, mechanical pain, bone lesion quality, spinal alignment, vertebral body collapse, and posterolateral involvement of the spinal elements, and corresponding scores were obtained [9]. Spinal stability was assessed by SINS system. In addition, patients were evaluated

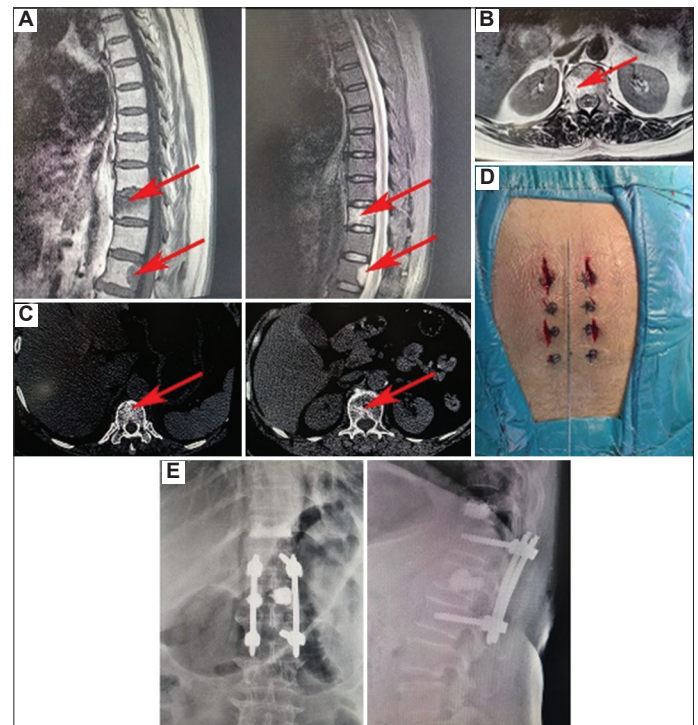


Figure 1. (A) Sagittal magnetic resonance imaging (MRI) shows a significant vertebral mass in T11 and L1, which was due to cancer metastasis in a 67-year-old woman. (B) Axial MRI shows a significant vertebral mass in L1. (C) Axial computed tomography shows lesions in the T11 and L1 vertebral bodies. (D) The picture shows the size of the wound after the operation. (E) Frontal and lateral views of the post-operative radiographs (Case 6).

according to the Tomita score (Table 2) and Modified Tokuhashi Scoring System (Table 3) [10-12].

2.4. Surgical procedure

All patients underwent spine surgery by the same experienced spine surgeon. All patients received PPSF combined with PVP in the prone position and intraoperative antibiotics were used to prevent infection, local infiltration anesthesia with or without profound sedation was performed during the operation. Before surgery, the body surface projection of the pedicle of the involved

vertebral body and adjacent upper and lower vertebral bodies were determined and marked under the guidance of fluoroscopic devices.

The first stage of the combined procedure was PVP. Under the guidance of the fluoroscopy device, puncture needles were placed into the pedicles on both sides of the diseased vertebral body. When the puncture needles reached the central site of bone destruction, biopsy forceps were used to remove part of the vertebral mass tissue, and pathological examination was carried out. PMMA was then slowly injected into the affected vertebra under fluoroscopic guidance. During the injection of PMMA, its diffusion within the vertebral body was carefully observed to confirm whether there was leakage into the vertebral canal and foraminal cavity, and the patient's vital signs were closely observed. The total amount of PMMA injected into each vertebral body was approximately 3–6 mL, and when the PMMA was close to the posterior edge of the vertebral body or a small amount of PMMA leaked out of the external vertebral space, the injection was stopped.

The second stage, PPSF, was also guided by a fluoroscopic device. Minimally invasive techniques were used to place pedicle screws successively into the bilateral pedicles of the adjacent upper and lower segments of the affected vertebra. The puncture position was in the outer upper quadrant of the vertebral pedicle, and the puncture needle angle was adjusted under the guidance of the fluoroscopic device to achieve the most satisfactory puncture effect. After the location and angle of the puncture were determined, four appropriately sized pedicle screws were placed sequentially, and fluoroscopy was used to confirm that the pedicle screws were in a good position (Figure 1D). Two rods of the appropriate length are then placed on the pedicle screws through the subcutaneous soft tissue and muscle to ensure normal curvature of the spine. After surgery, all patients underwent X-rays to determine whether the internal fixation was in a good position and whether the cement was leaking (Figure 1E).

All patients received follow-up therapy, such as radiotherapy and chemotherapy, to control any further progression of the tumor and to avoid further compression of the neural structure. The PPSF system and PMMA were provided by the Weigao Medical Instruments (Shandong, China).

2.5. Clinical follow-up

All patients underwent X-ray re-examination at the end of surgery and 7 days, 3 months, and 6 months after the operation.

Table 1. Spinal instability neoplastic scoring system

Category	Score
Location	
Junctional (occiput-C2, C7-T2, T11-L1, L5-S1)	3
Mobile spine (C3-C6, L2-L4)	2
Semirigid (T3-T10)	1
Rigid (S2-S5)	0
Pain*	
Yes	3
Occasional pain but not mechanical	1
Pain-free lesion	0
Bone lesion phenotype	
Lytic	2
Mixed (lytic/blastic)	1
Blastic	0
Spinal alignment (radiography)	
Subluxation/translation present	4
De novo deformity (kyphosis/scoliosis)	2
Normal alignment	0
Vertebral body collapse	
>50% collapse	3
<50% collapse	2
No collapse with >50% body involved	1
None of the above	0
Posterolateral involvement of spinal elements**	
Bilateral	3
Unilateral	1
None of the above	0

*Mechanical or postural pain is scored in this section. Relief with recumbency supports a structural or mechanical component. **This section includes pedicles, facets, and costovertebral joints.

Table 2. Tomita score prognostic factors and treatment strategies.

Score	Primary tumor	Visceral metastases	Bone metastasis
1	Slow growth (breast, thyroid, etc.)	None	Solitary
2	Moderate growth (kidney, uterus, etc.)	Treatable	Multiple
4	Rapid growth (lung, stomach, etc.)	Not treatable	
Prognostic score	Treatment goals	Surgical strategy	
2 – 3	Long-term local control	Extensive or marginal resection	
4 – 5	Mid-term local control	Marginal or intralesional resection	
6 – 7	Short-term local control	Palliative care	
8 – 10	Symptomatic treatment	Supportive treatment	

Table 3. Modified Tokuhashi scoring system

Prognosis parameter	Score
General condition (performance status)*	
Poor (10 – 40%)	0
Moderate (50 – 70%)	1
Good (80 – 100%)	2
Number of bone metastases outside spine	
≥3	0
1 – 2	1
0	2
Number of metastases in spinal cord	
≥3	0
2	1
1	2
Metastasis to major organs	
Unremovable	0
Removable	1
No metastases	2
Primary tumor location	
Lung, osteosarcoma, stomach, bladder, esophagus, pancreas	0
Liver, gallbladder, unidentified	1
Other	2
Kidney, uterus	3
Rectum	4
Thyroid, breast, prostate, carcinoid tumor	5
Spinal cord damage	
Complete paraplegia	0
Incomplete paraplegia	1
None	2

*Performance status according to Karnofsky

Post-operative complications, including wound dehiscence, infection, and pedicle screw loosening, were recorded. The BIADL and VAS were used to evaluate QoL and pain, respectively. Data were collected from all patients on the day of surgery and 7 days, 3 months, and 6 months after surgery.

2.6. Statistical analysis

The data were recorded in SPSS 24.0 software (SPSS, Chicago, IL, USA) and analyzed. Measurement data were reported as mean and standard deviation, and repeated measures of variance analysis were used to analyze the clinical outcomes (VAS score for pain assessment, BIADL scores for improved functionality) at different times. $P \leq 0.05$ was considered statistically significant.

3. Results

All operations were successfully completed. There were no puncture injury, spinal cord or nerve root compression symptoms, intraspinal hemorrhage during operation, and no serious complications such as infection and pulmonary embolism after operation. All patients underwent post-operative X-ray examination, which showed that the position of the internal fixation was good, there was no leakage of bone cement, and the

bone cement was filled in the location of osteolytic destruction in the vertebral body. We recorded the following information: age, sex, type of primary tumor, diseased vertebral body, volume of PMMA injected, and survival time (Tables 4 and 5).

All patients were evaluated preoperatively. The mean SINS was 12.4 (range: 9.0 – 16.0) for spinal instability. According to the Tomita scoring system, the average prognostic score was 5.6 (range: 3.0 – 8.0). According to the Modified Tokuhashi Scoring System, the average prognostic score was 9.0 (range: 5.0 – 14.0). No epidural spinal cord compression was found on MRI images in any of the patients.

Forty cases were operated successfully. No patients had syndromes such as PMMA leakage or nerve injury. The median operation time was 55.2 min (range: 40.0–90.0 min), the median blood loss was 45.8 mL (range: 20.0–85.0 mL), and the median dose of PMMA injected was 3.8 mL (range: 1.5–8.5 mL). In all patients, postoperative radiology showed satisfactory internal fixation and good PMMA dispersion.

In this study, 40 patients were followed up for 6.0–33.0 months (the average time was 14.9 months). The surgery was very successful. There were no complications, such as infection, pedicle screw loosening, or PMMA oozing. There were no deaths due to complications of the operation itself.

The average VAS score for the 40 patients decreased from 6.8 ± 2.0 before the operation to 3.2 ± 1.5 at 7 days after the operation, 0.7 ± 1.0 at 3 months after the operation, and 0.5 ± 0.7 at 6 months after the operation. The BIADL score increased from 41.9 ± 14.5 preoperatively to 62.9 ± 17.4 at 7 days after the operation, 86.1 ± 13.9 at 3 months after the operation, and 93.9 ± 6.8 at 6 months after the operation (Figure 2A-C and Table 6). The median overall survival was 14.5 months (Figure 2D).

4. Discussion

In recent years, with the development of comprehensive tumor therapy, the extension of survival time of tumor patients, and the widespread use of MRI, the remedy of spinal metastasis has become a common clinical issue. In the meantime, with the development of remedies for spinal metastases and the improvement of spinal surgery techniques, surgery has become one of the main approaches to spinal metastases. This study incorporated 40 patients, all of whom underwent PPSF combined with PVP after a detailed pre-operative evaluation. All patients successfully completed the operation. All patients underwent post-operative X-ray examination, which showed that the position of the internal fixation was good, there was no leakage of bone cement, and the bone cement was filled in the location of osteolytic destruction in the vertebral body. No surgery-related complications occurred in all patients. The VAS scores of all patients were significantly decreased and the BIADL scores were significantly increased after operation. This result showed significant pain relief and improved quality of life after PVP combined with PPSF. Therefore, in general, PVP combined with PPSF is safe in the treatment of multilevel vertebral metastasis, which can achieve satisfactory clinical results for patients

Table 4. Summary of the clinical data of the patients

Patient	Gender	Age (year)	Primary tumor	Metastasis to other organs	Diseased vertebral body	SINS score	Dose of PMMA (mL)	Survival (months)
1	F	53	Breast cancer	Lung	T12, L2, L3	15	6	11
2	F	61	Lung cancer	--	T10, L1, L3	13	3	8
3 ^a	F	76	Breast cancer	Cardia	T11, L3, L4	15	3	9
4	M	65	Lung cancer	--	T11, L4	13	4	12
5	F	68	Esophageal cancer	--	T5, T11, L2	10	1.5	25
6	F	67	Cervical cancer	--	T11, L1	11	3	6
7 ^b	F	70	Esophageal cancer	--	T8, T12, L2, L3	11	3	15
8	M	68	Esophageal cancer	Lung	T10, T11, T12, L1	12	5	7
9	M	61	Lung cancer	Liver	T12, L3	10	3	20
10	F	57	Lung cancer	--	T9, T11, L3, L4	13	3	18
11	F	60	Lung cancer	--	T11, T12, L2, L3	14	6	16
12	F	64	Lung cancer	--	T9, T12, L1	10	1.5	14
13 ^c	M	64	Lung cancer	--	T11, T12, L3	14	6	13
14	M	72	Lung cancer	--	T10, T11, L4, L5	12	2	7
15 ^d	F	67	Lung cancer	--	T8, T9, L1, L2	16	3	21
16	F	30	Lung cancer	--	T10, T12, L1	10	2	9
17	M	64	Lung cancer	--	T10, T11, L2, L3	11	2	13
18	M	73	Lung cancer	--	T7, T11, L2	13	3	16
19	F	58	Renal cancer	Suprarenal gland	T7, T11, T12, L4	14	5	21
20	F	56	Multiple myeloma	--	T11, T12, L3, L4	15	8.5	16
21	M	62	Lung cancer	--	T11, L4	11	4	10
22	M	62	Renal cancer	Lung	T11, L1, S2	13	3	9
23 ^e	M	56	Lung cancer	Liver	T10, L1, L2	16	1.5	16
24	F	50	Breast cancer	Liver	T11, L2, L3, L5	14	4	14
25	F	57	Breast cancer	--	T12, L1, L2	11	3	17
26	F	38	Lung cancer	--	T10, L3, L4	10	3	16
27	M	69	Lung cancer	Encephalon	T11, L3	15	3	14
28	F	63	Lung cancer	--	T12, L1	13	2,5	19
29	M	81	Renal cancer	Lung	T11, T12, L2	14	4	12
30	F	53	Lung cancer	--	T10, L2	15	3	15
31	M	56	Lung cancer	--	T10, L2	13	4.5	13
32	M	73	Hepatic carcinoma	--	T11, T12, L1	11	3	9
33	F	36	Lung cancer	Liver, encephalon	T11, T12, L2	10	3	26
34	F	86	Breast cancer	--	T2, L3	14	4.5	15
35	F	45	Breast cancer	--	T8, T9, L2	10	7	18
36	F	65	Lung cancer	Encephalon	T11, T12, L5	9	4.5	17
37	M	77	Lung cancer	--	L1	14	3.5	18
38	M	60	Renal cancer	--	T12, L1	10	5.5	13
39	F	28	Breast cancer	Liver, lung	L5, S1	13	5	14
40	F	69	Breast cancer	Lung	T12, L3	9	6.5	33

^{a-c}These patients died of underlying diseases, not from surgery, at 9, 15, 13, 16, and 21 months, respectively. M: Male; F: Female, PMMA: Polymethylmethacrylate, SINS: Spinal instability neoplastic score

and clinicians, and significantly improve the quality of life of patients.

Bone metastases often lead to bone damage, pathological fractures, pain, compressive myelopathy, spinal instability, and other adverse events. About 90% of the fractures require surgical treatment [13,14]. Skeletal metastasis often occurs in the spine, ribs, pelvis, and proximal femur but rarely in the upper limb bones

and skull [15]. The cervical vertebrae and sacral vertebrae are less frequently involved [16]. The remedy of spinal metastases is complex and challenging, demanding systematic and local treatment with a multidisciplinary program, including surgical approaches, targeted treatment and radiation therapy.

Patients with metastatic malignancy often face a poor prognosis and are generally not suitable for surgical removal of the primary

Table 5. Clinical data of 40 patients with spinal metastases

Clinical data	
Age (year)	61.0±12.6
Gender	
Male	16
Female	24
Primary tumor	
Lung cancer	22
Breast cancer	8
Kidney cancer	4
Esophageal cancer	3
Cervical cancer	1
Multiple myeloma	1
Liver cancer	1
VAS score	6.8±2.0
BIADL score	41.9±14.5

VAS: Visual analog scale, BIADL: Barthel Index of activities of daily living

Table 6. Changes in VAS and BIADL from initial assessment to final follow-up.

	Before surgery	7 days	3 months	6 months	F	P-value
VAS score	6.82±1.96	3.2±1.5	0.73±1.01	0.48±0.72	181.5	<0.05
BIADL score	41.88±14.49	62.9±17.4	86.1±13.9	93.9±6.8	204.9	<0.05

VAS: Visual analog scale, BIADL: Barthel Index of activities of daily living

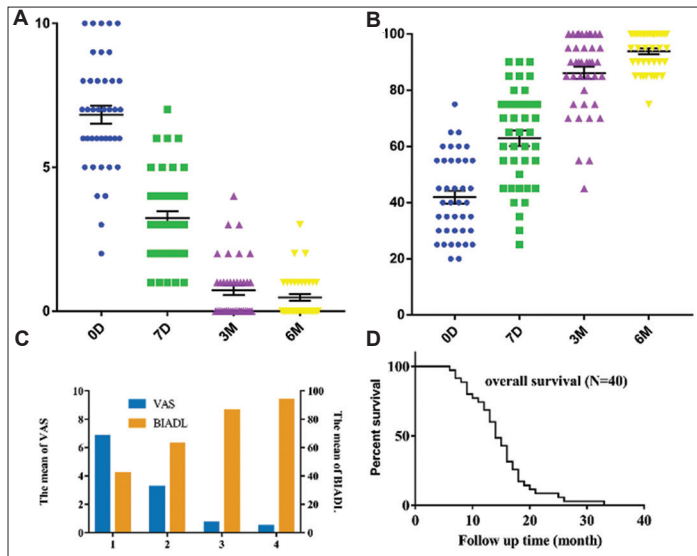


Figure 2. (A) Visual analog scale (VAS) scores for pain. (B) Barthel Index of activities of daily living (BIADL) scores for patient quality of life. (C) Changes in VAS and BIADL scores after percutaneous pedicle screw fixation combined with percutaneous vertebroplasty. (D) Overall survival curve.

neoplasms, and elderly patients in general are often not suitable for extensive open spinal surgery under general anesthesia to remove the damaged tissue. These factors greatly limit treatment. The main

purpose of treatment for end-stage patients is to ease pain and maintain or restore living quality, and palliative care is often chosen. Surgery, while not the only treatment, can improve spinal stability, prevent pathological fractures, effectively ease pain, and improve the quality of life. Many minimally invasive techniques have been introduced into the clinic. These technologies can reduce complications, maintain the integrity of the spinal ligaments, reduce the risk of blood loss and infection, and accelerate post-operative recovery, and almost all patients can walk on the first day after surgery.

PVP, a non-invasive procedure in which PMMA is injected into the centrum to ease pain and stabilize the spine, improves the stability of the centrum and avoids the adverse events associated with open surgery [17]. Liu *et al.* used PVP to treat 50 patients with metastatic spine tumors, and all attained good clinical effects [18]. PVP for spinal tumors can ease pain, improve quality of life, and improve the prognosis of patients with metastatic spinal tumors [19]. Nevertheless, PVP can lead to infection, leakage of PMMA, and refracture and collapse of the vertebra after surgery [20]. Leakage of PMMA into the spinal canal can cause mechanical compression and associated neurological symptoms, and if it leaks into the veins, it can cause pulmonary embolism. PPSF should be preferred in patients with ruptured posterior walls and poor spinal stability [21]. Severe osteoporosis is an important factor for vertebral refracture collapse during surgery. The lower the bone density of patients before surgery, the more likely they are to suffer vertebral collapse [22]. If the intraoperative PMMA filling is insufficient, the strength of the vertebral body cannot be recovered well, and post-operative collapse can easily recur.

Compared to vertebroplasty, PPSF can achieve efficient and lasting stability, reduce the pressure above and below the affected vertebra, and partially restore the height of the affected vertebra. Zairi *et al.* treated 44 patients with symptomatic thoracic and lumbar vertebrae metastatic tumor with PPSF, and underwent post-operative radiotherapy within 2 weeks after stabilization. The patients were followed up for 6 – 12 months and found that the pain was significantly relieved, and no adverse events such as dislocation, hardware damage, or loosening occurred during follow-up [23].

Gu *et al.* performed minimally invasive pedicle screw fixation combined with PVP for spinal decompression and partial resection of the tumor in patients with thoracolumbar metastatic tumors. The VAS score was dramatically reduced after the operation, and the motor sensory function of most patients returned to normal. No changes in spinal curvature or vertebral height were observed during the follow-up, and the spine was considered stable, confirming the effectiveness of the treatment [24].

None of the patients in our study had neurological symptoms, so open spinal decompression was not needed. In combination treatment, PMMA perfusion in PVP has a better supporting function for the affected vertebrae, can reduce the stress of upper and lower pedicle screws, reduce the stress of internal fixation, and effectively avoid the failure of internal fixation. Similarly, pedicle screws can reduce the volume of PMMA injection, stabilize the adjacent centrum, and reduce PMMA side effects.

In summary, the remedy for metastatic spine tumors is mainly palliative care, so minimally invasive techniques are first adopted

to reduce the impact of surgery on critically ill patients, combined with early postoperative radiotherapy to control the tumors and prevent further compression of the spinal cord. We believe that PPFs combined with PVP is an effective treatment for thoracic and lumbar metastatic tumors, which can ease the pain of the patients and improve their quality of life.

This study has some limitations. First, our study design is not a randomized and case-control study but a retrospective study. In addition, we did not set a control group to compare the clinical efficacy. Therefore, our findings cannot be applied to all patients with asymptomatic thoracolumbar metastases. Second, only 40 patients were analyzed and followed up. To better determine the clinical efficacy and prognosis of this operation, the follow-up time and the number of patients should be increased.

Acknowledgments

None.

Funding

Not applicable.

Conflicts of Interest

There are no ethical/legal conflicts involved in the article.

Ethics Approval and Consent to Participate

Not applicable.

References

- [1] Piccioli A, Maccauro G, Spinelli MS, Biagini R, Rossi B. Bone Metastases of Unknown Origin: Epidemiology and Principles of Management. *J Orthop Traumatol* 2015;16:81-6.
- [2] Jiang L, Cui X, Ma H, Tang X. Comparison of Denosumab and Zoledronic Acid for the Treatment of Solid Tumors and Multiple Myeloma with Bone Metastasis: A Systematic Review and Meta-Analysis Based on Randomized Controlled Trials. *J Orthop Surg Res* 2021;16:400.
- [3] Errani C, Mavrogenis AF, Tsukamoto S. What's New in Musculoskeletal Oncology. *BMC Musculoskelet Disord* 2021;22:704.
- [4] Hammad A, Wirries A, Ardeshiri A, Nikiforov O, Geiger F. Open Versus Minimally Invasive Tlif: Literature Review and Meta-Analysis. *J Orthop Surg Res* 2019;14:229.
- [5] Yuan L, Bai J, Geng C, Han G, Xu W, Zhang Z, et al. Comparison of Targeted Percutaneous Vertebroplasty and Traditional Percutaneous Vertebroplasty for the Treatment of Osteoporotic Vertebral Compression fractures in the Elderly. *J Orthop Surg Res* 2020;15:359.
- [6] Li Q, Long X, Wang Y, Guan T, Fang X, Guo D, et al. Clinical Observation of Two Bone Cement Distribution Modes after Percutaneous Vertebroplasty for Osteoporotic Vertebral Compression Fractures. *BMC Musculoskelet Disord* 2021;22:577.
- [7] He W, He D, Sun Y, Xing Y, Wen J, Wang W, et al. Standalone Oblique Lateral Interbody Fusion vs. Combined with Percutaneous Pedicle Screw in Spondylolisthesis. *BMC Musculoskelet Disord* 2020;21:184.
- [8] Fisher CG, DiPaola CP, Ryken TC, Bilsky MH, Shaffrey CI, Berven SH, et al. A Novel Classification System for Spinal Instability in Neoplastic Disease: An Evidence-Based Approach and Expert Consensus from the Spine Oncology Study Group. *Spine (Phila Pa 1976)* 2010;35:E1221-9.
- [9] Murtaza H, Sullivan CW. Classifications in Brief: The Spinal Instability Neoplastic Score. *Clin Orthop Relat Res* 2019;477:2798-803.
- [10] Ulmar B, Huch K, Naumann U, Catalkaya S, Cakir B, Gerstner S, et al. Evaluation of the Tokuhashi Prognosis Score and its Modifications in 217 Patients with Vertebral Metastases. *Eur J Surg Oncol* 2007;33:914-9.
- [11] Shamseddeen H, Pike F, Ghabril M, Patidar KR, Desai AP, Nephew L, et al. Karnofsky Performance Status Predicts Outcomes in Candidates for Simultaneous Liver-Kidney Transplant. *Clin Transplant* 2021;35:e14190.
- [12] Kubota H, Soejima T, Sulaiman NS, Sekii S, Matsumoto Y, Ota Y, et al. Predicting the Survival of Patients with Bone Metastases Treated with Radiation Therapy: A Validation Study of the Katagiri Scoring System. *Radiat Oncol* 2019;14:13.
- [13] Kong Y, Ma XW, Zhang QQ, Zhao Y, Feng HL. Gastrointestinal Stromal Tumor with Multisegmental Spinal Metastases as First Presentation: A Case Report and Review of the Literature. *World J Clin Cases* 2021;9:1490-8.
- [14] Duo J, Han X, Zhang L, Wang G, Ma Y, Yang Y. Comparison of FDG PET/CT and Gadolinium-Enhanced MRI for the Detection of Bone Metastases in Patients with Cancer: A Meta-Analysis. *Clin Nucl Med* 2013;38:343-8.
- [15] Plancarte-Sanchez R, Guajardo-Rosas J, Cerezo-Camacho O, Chejne-Gomez F, Gomez-Garcia F, Meneses-Garcia A, et al. Femoroplasty: A New Option for Femur Metastasis. *Pain Pract* 2013;13:409-15.
- [16] Liu Y, Sheng J, Dong Z, Xu Y, Huang Q, Pan D, et al. The Diagnostic Performance of ¹⁸F-Fluoride PET/CT in Bone Metastases Detection: A Meta-Analysis. *Clin Radiol* 2019;74:196-206.
- [17] Orgera G, Krokidis M, Rebonato A, Tipaldi MA, Mascagni L, Rossi M. Thyroid Skeletal Metastasis: Pain Management with Vertebroplasty. *BMJ Support Palliat Care* 2019;9:e2.
- [18] Liu Y, Wang Y, Zhao L, Song R, Tan H, Wang L. Effectiveness and Safety of Percutaneous Vertebroplasty in the Treatment of Spinal Metastatic Tumor. *Pak J Med Sci* 2017;33:675-9.
- [19] Qi L, Li C, Wang N, Lian H, Lian M, He B, et al. Efficacy of Percutaneous Vertebroplasty Treatment of Spinal Tumors: A Meta-Analysis. *Medicine (Baltimore)* 2018;97:e9575.

- [20] Park JW, Park SM, Lee HJ, Lee CK, Chang BS, Kim H. Infection Following Percutaneous Vertebral Augmentation with Polymethylmethacrylate. *Arch Osteoporos* 2018;13:47.
- [21] Mansour A, Abdel-Razeq N, Abuali H, Makoseh M, Shaikh-Salem N, Abushalha K, *et al.* Cement Pulmonary Embolism as a Complicaztion of Percutaneous Vertebroplasty in Cancer Patients. *Cancer Imaging* 2018;18:5.
- [22] Kim HS, Heo DH. Percutaneous Pedicle Screw Fixation with Polymethylmethacrylate Augmentation for the Treatment of Thoracolumbar Intravertebral Pseudoarthrosis Associated with Kummell's Osteonecrosis. *Biomed Res Int* 2016;2016:3878063.
- [23] Zairi F, Vielliard MH, Bouras A, Karnoub MA, Marinho P, Assaker R. Long-Segment Percutaneous Screw Fixation for Thoraco-Lumbar Spine Metastases: A Single Center's Experience. *J Neurosurg Sci* 2017;61:365-70.
- [24] Gu Y, Dong J, Jiang X, Wang Y. Minimally Invasive Pedicle Screws Fixation and Percutaneous Vertebroplasty for the Surgical Treatment of Thoracic Metastatic Tumors with Neurologic Compression. *Spine (Phila Pa 1976)* 2016;41 Suppl 19:B14-22.

Publisher's note

Whioce Publishing remains neutral with regard to jurisdictional claims in published maps and institutional affiliations.